

Sequential infiltration of sodium hyaluronate in the temporomandibular joint with different molecular weights. Case report

Infiltração sequencial de hialuronato de sódio com diferentes pesos moleculares na articulação temporomandibular. Relato de caso

Eduardo Grossmann¹, Roberta Fonseca², Camila Almeida-Leite², Rafael Tardin Gonçalves³, Pedro Gonçalves de Oliveira⁴, Eduardo Januzzi³

DOI

ABSTRACT

BACKGROUND AND OBJECTIVES: Temporomandibular disorders are diseases causing pain and dysfunction in joints and muscles controlling mandibular movements. Their etiology is multifactorial and multidisciplinary approaches are needed to reach a differential diagnosis and an adequate management plan. This case report proposes a management protocol, with monthly sodium hyaluronate infiltrations, with different molecular weights, to control such changes and promote improvement of temporomandibular joint biomechanics and pain.

CASE REPORT: This study describes a case of a 48-year old patient with a 10-year history of temporomandibular pain with function loss since 2001. Patient has classified her pain as 9 according to analog visual scale. In addition, history and detailed physical evaluation have shown different signs and symptoms, such as localized pain (right side), and right temporomandibular joint arthralgia with noise. Diagnosis was disc displacement with reduction and possible synovitis/capsulitis to the right. Right temporomandibular joint osteoarthritis was also diagnosed by cone beam CT-scan. Initially, a flat upper splint with total coverage and contact with all antagonist teeth was used. In the attempt to decrease temporomandibular arthralgia, non-steroid anti-inflammatory drugs and muscle relaxants were used. Since right temporomandibular joint pain was not effectively managed, we decided to use intra-joint sodium hyaluronate injections with different molecular weights, per month, in a total of four applications. At treatment completion, clinical evaluation has shown normal function, no pain with visual analog scale = zero, in addition to adequate interincisal distance.

CONCLUSION: This report has suggested that viscosupplementation cycles with sodium hyaluronate of different molecular weights may provide excellent results in the long run, to control joint temporomandibular disorder symptoms. Therapeutic benefits were main-

tained for four years with no need for annual maintenance cycles.

Keywords: Disk displacement with reduction, Sodium hyaluronate, Temporomandibular joint, Viscosupplementation.

RESUMO

JUSTIFICATIVA E OBJETIVOS: As disfunções temporomandibulares são um grupo de doenças que causam dor e disfunção na articulação e nos músculos que controlam os movimentos da mandíbula. Sua etiologia é multifatorial e abordagens multidisciplinares são necessárias para chegar a um diagnóstico diferencial e plano de tratamento adequado. Propõe-se um protocolo de tratamento, com infiltrações mensais, empregando hialuronato de sódio, com diferentes pesos moleculares, para controlar essas alterações e promover uma melhoria da função biomecânica da articulação temporomandibular, bem como da sua dor.

RELATO DO CASO: Este estudo descreve um caso de uma paciente de 48 anos que apresentava uma história de 10 anos de dor temporomandibular com perda de função que apareceu em 2001. Ela classificou a intensidade da sua dor como grau 9 de acordo com a escala visual analógica. Além disso, anamnese e exame clínico detalhado mostraram diversos sinais e sintomas, como dor localizada miofascial (lado direito), artralgia da articulação temporomandibular direita com ruído. O diagnóstico foi de deslocamento de disco com redução e possível sinovite/capsulite à direita. Osteoartrose da articulação temporomandibular direita também foi confirmada por tomografia computadorizada de feixe cônico. Inicialmente, foi utilizada uma placa superior plana de cobertura total com contato com todos os dentes antagonistas. Numa tentativa de diminuir a artralgia temporomandibular, foram empregados anti-inflamatórios não esteroides e um relaxante muscular. Como a dor da articulação temporomandibular direita não foi efetivamente eliminada, optou-se pela utilização de uma injeção intra-articular de hialuronato de sódio, com diferentes pesos moleculares, por mês, totalizando quatro aplicações. No final do tratamento, o exame clínico mostrou normalização da função, a dor havia desaparecido, escala analógica visual=zero, além de uma distância interincisal adequada.

CONCLUSÃO: O presente trabalho sugeriu que ciclos de viscosuplementação com hialuronato de sódio, de diferentes pesos moleculares, podem proporcionar excelentes resultados, em longo prazo, no controle de sinais e sintomas da disfunção temporomandibular de origem articular. Os benefícios terapêuticos foram mantidos por um período de quatro anos, sem a necessidade de ciclos anuais de manutenção.

Descritores: Articulação temporomandibular, Deslocamento do disco com redução, Hialuronato de sódio, Viscosuplementação.

1. Universidade Federal do Rio Grande do Sul, Porto Alegre, RS, Brasil.

2. Universidade Federal de Minas Gerais, MG, Brasil.

3. Ciodonto, Belo Horizonte, MG, Brasil.

4. Universidade Anhembi, São Paulo, SP, Brasil.

Submitted in July 27, 2015.

Accepted for publication in October 13, 2015.

Conflict of interests: none – Sponsoring sources: none.

Correspondence to:

Eduardo Grossmann

Rua Coronel Corte Real, 513, Bairro Petrópolis.

90630-080 Porto Alegre, RS, Brasil.

E-mail: edugdor@gmail.com

INTRODUCTION

Among temporomandibular disorders (TMD), disc displacement with or without reduction, osteoarthritis and osteoarthritis are the most prevalent diseases in patients that seek for treatment^{1,2}.

Considering therapies which are minimally invasive, some studies have shown that the use of intra-articular infiltration of sodium hyaluronate (SH) in the upper articular cavity and, sometimes, in both cavities, is effective for treating intra-articular abnormalities in patients with TMJ disorders³⁻⁵.

Hyaluronic acid (HA), which is usually present in the organism as SH, is a polyionic hydrophilic linear chain glycosaminoglycan of high molecular weight. It is usually found in the extracellular matrix of the connective tissue, including the articular cartilage and synovial fluid⁶⁻⁸, where SH molecules are mainly synthesized by sinovial B cells^{9,10}. The metabolic activity of SH in cell renewal and its combination with glycosaminoglycan, originated from proteoglycans produced by chondrocytes, facilitate the nourishment of avascular zones of the disc and the articular cartilage⁵⁻¹¹.

Increases in proteoglycans synthesis, as well as in the production of metalloproteinase (MP), are observed in pathological conditions. MP acts over collagen and proteoglycans weakening the articular cartilage matrix, generating fragments of collagen and proteoglycans, as well as leukotrienes and cytokines, which become disperse in the articular fluid. Such process generates an inflammatory response in the synovial membrane and capsular ligament, which may limit the articular movement and cause pain^{11,12}.

Therefore, the intraarticular use of SH, according to its molecular weight, may increase its endogenous production by synovial cells and improve or normalize mandibular functions, releasing early stages adherence or adhesiveness between the fossa and the articular disc^{5,13}.

Despite the use of SH in viscosupplementation therapy, it is necessary to highlight that very high molecular weight molecules (between 1 and 6×10^6 Da) are prevented from passing from the intraarticular environment to the intercellular environment, being then incapable of acting on synoviocytes and chondrocytes, which would be necessary to reduce synovial inflammation and restore the natural properties of the synovial fluid, being it recently called "visco-induction"^{8,10,14}.

According to this theory, products with molecular weight between 0.5 and 1×10^6 Da present the best *in vivo* effects, being capable of producing the synthesis of endogenous HA by synoviocytes. Likewise, other researchers established an even narrower molecular weight range (500-730 kDa) as the one capable of acting on the synovial fibroblasts and restoring their capacity of synthesizing hyaluronic acid^{5,8,12}.

TMJ viscosupplementation is a minimally invasive technique that consists in intra-articular injection of HA aiming at eliminating or diminishing the pain and improving articulation functional activity, which would improve the qualitative and quantitative quality of the synovial fluid⁵.

Due to HA mechanical and metabolic characteristics, viscosupplementation, isolated or combined with another surgical modalities, such as arthrocentesis and arthroscopy¹⁵⁻²⁰, may be a therapeutic option to inflammatory conditions and biomechanical alterations of the TMJ, being it an ideal conservative treatment, as it has been

considered minimally invasive and has presented no deleterious effects so far^{5,6,13}.

This paper describes a protocol of treatment that uses sequential infiltration of HA, of different molecular weights, for treating intra-articular alterations of TMJ accompanied by functional limitation and pain.

CASE REPORT

This study describes the case of a 48 year-old female patient who presents a 10-year history of temporomandibular pain and impaired function.

Patient described that her first symptoms appeared in 2001, when she began working, and that they worsened for the next ten years. During that time she felt facial distress, pain, discomfort and the right TMJ made noises during mastication. She classified the intensity of her pain as degree 9 according to the visual analog scale (VAS), and reported that nervousness and anxiety made the pain worse. She tried to live with the symptoms for a number of years, but then they became worse, pain increased and she finally sought for medical care.

The dentist diagnosed her with temporomandibular disorder. She experienced pain when performing mandibular functional activities and had her sleep disturbed at night. Furthermore, she experienced extreme jaw stiffness in the morning with episodes of locking joint and interincisal distance of 32.28mm (measured with digital caliper, Vonder® - 150mm) (Figure 1).

Further careful anamnesis and detailed clinical examination showed several signs and symptoms, such as localized myofascial pain (right side), arthralgia of the right temporomandibular joint (TMJ) with noise. Patient also experienced pain under electric




Figure 1. Limitation of the interincisal distance

shock, pressure of short duration over the joint and deviation of the mandibular trajectory to the right.

The diagnosis was of disc displacement with reduction and possible synovitis/capsulitis on the right. Osteoarthritis of the right TMJ was also confirmed by cone beam computed tomography.

Initially, the treatment aimed at minimizing the overload on the TMJ caused by sleep bruxism. Therefore, an upper flat occlusal splint with full coverage, thermo-polymerized and bilateral contact with antagonist teeth was used. In an attempt of diminishing the temporomandibular arthralgia, a non-steroidal anti-inflammatory was also used for the first 12 days (Tenoxicam, 20mg), at every 12 hours, along with a muscle relaxant (cyclobenzaprine, 5mg) two hours before sleeping. The dose of muscle relaxant was increased to 10mg in an attempt to control myalgia that accompanied arthralgia. After six months using 10mg cyclobenzaprine the dose was reduced to 5mg again, as the pain was reduced to degree 3 in the VAS, and the medicine was gradually withdrawn in alternate days until the end of the seventh month.

A nuclear magnetic resonance was requested before the beginning of the treatment to measure the position and morphology of the articular disc and to verify the type and possible location of the effusion. However, for economical reasons, patient could not perform the test.

As pain in right the TMJ was not effectively eliminated, the solution found was to use a minimally invasive therapy with sodium hyaluronate, and the patient received four intra-articular injections of SH with different molecular weights per month. The solution with the lowest molecular weight (500-730 kDa - Polireumin[®]) SH was used in the first and third months and the SH solution with higher molecular weight (1,000 – 2,000 kDa – Osteonil Mini[®]) in the second and fourth months.

The procedure was conducted as follows. Patient sat comfortably in a chair with an inclination of 45°. She was instructed to rotate her head towards the asymptomatic side to facilitate the approach to the symptomatic TMJ. The pre-auricular area was then disinfected with 70% alcohol and povidone[®]. Lidocaine (1.8mL), without vasoconstrictor, was used to block the auricular nerve¹⁷. After 3 minutes the area under anesthesia was tested with a probe n° 5. Afterwards, 1mL/cc syringe BD and gauge needle 0,80x25 mm (21G) were used for the intra-articular joint injection. The needle was inserted 10mm anterior to the tragus and 2mm below the tragus line – external corner of the orbital cavity (Homlund line). The needle was directed anteriorly, superiorly, and medially until the tip of it reached the glenoid fossa close to the upper joint space (Figure 2).

One milliliter of SH was injected in the upper joint space and, as procedure went on, the substance was aspirated to verify if it was not being injected into a blood vessel (superficial temporal vein or artery), or in the vascular part located along the retrodiscal area. Patient was then instructed to move the lower jaw actively, but without the operator manipulation.

There was a protocol (1st, 2nd, 3rd, 4th month) to be followed the day following SH application to verify the mandibular amplitude and the intensity of the articular pain.

At the end of the treatment, her clinical examination showed the full restoration of the function. Besides, pain had disappeared,

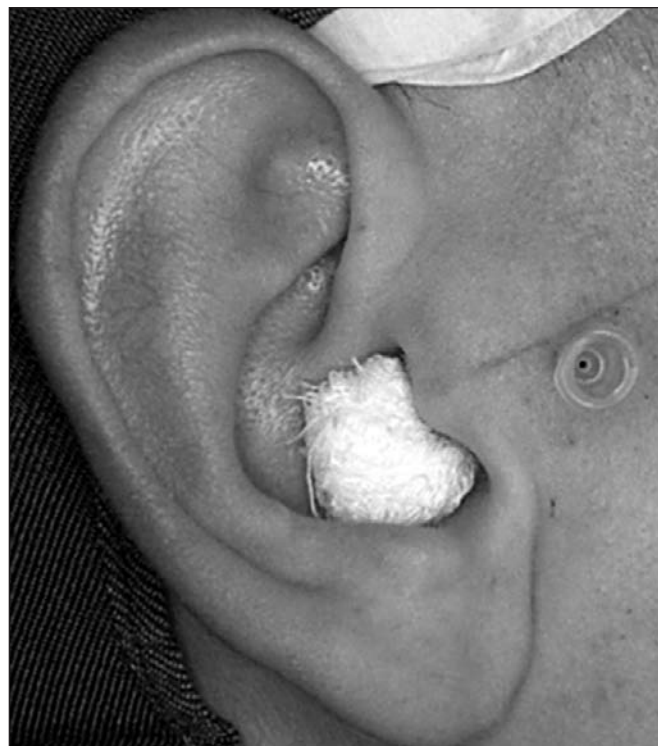

Figure 2. The needle was inserted 10mm anterior to the tragus and 2mm below the tragus line – external corner of the orbital cavity. It was directed anteriorly, superiorly, and medially until the tip of it reached the glenoid fossa close to the upper joint space of the right TMJ

VAS=zero and she presented an adequate interincisal distance (Figure 3).

Patient remained without pain or TMJ dysfunction after a 4-year follow up.

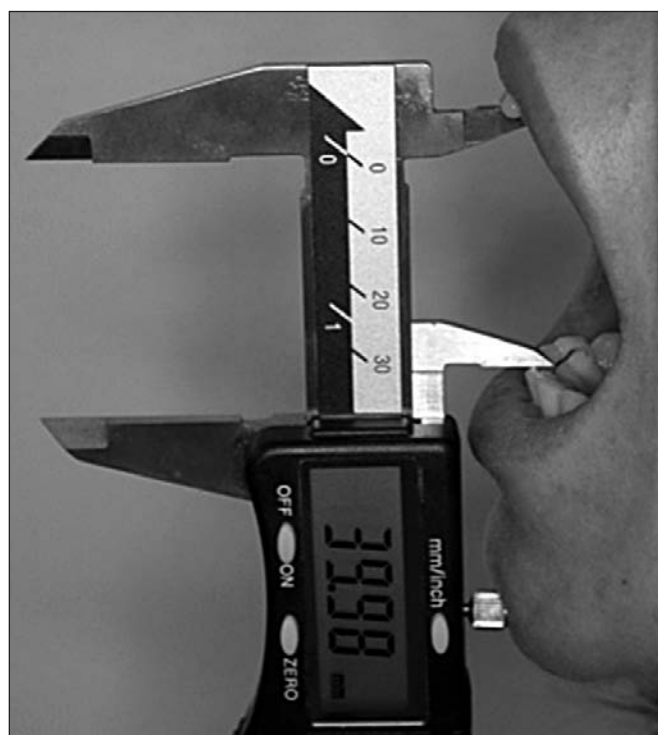

Figure 3. Four year follow-up showed an adequate interincisal distance

DISCUSSION

TMJ is a diarthrodial synovial joint with peculiar characteristics, as it has three bone components: the condyle, the articular tubercle and the mandibular fossa of the temporal bone. It has also a fibrocartilaginous joint disc located between the condyle and the articular fossa, which divides the articular cavity in upper and lower cavities. The articular disc in adults is avascular, presents a biconcave shape and is composed by three segments: anterior, intermediate and posterior bands, being the latest the thickest one^{21,22}. Each TMJ is considered a ginglymus joint, as it allows hinge movements in one axis and sliding movements in another²³. The synovial fluid that fills the upper and lower articular cavities is responsible by the nourishment and lubrication of the articular tissues, being its quantity and quality directly related to the articular health and function²². Many studies have demonstrated changes in the synovial fluids of TMJ with disorders, which cause temporomandibular pain²³⁻²⁹. Our study presented a case where the patient underwent disc displacement with reduction associated to effusion. Whenever the patient performed the maneuver of mandibular translation, the anterior area of the condyle pressed the retrodiscal area, dislocated from its original innervated and vascularized site, pain was produced, as an electric shock. The second pain was probably caused by the algogenic substances present in the right upper cavity, which generated localized extra pressure when the mandible moved and, consequently, pain. Both algias were not eliminated by the use of the occlusal splint associated to a painkiller and a muscle relaxant of central action.

The hyaluronic acid is present in the synovial fluid and in the cellular matrix of various connective tissues³⁰. It acts in the articular lubrication, reducing the friction in the intra-articular spaces and contributing to the diminishment of the adhesiveness and of inflammatory mediator levels, which would be related to the relief of pain. Its metabolic activity contributes to cell renewal and facilitates the nourishment of avascular areas of the disc and articular cartilage due to its combination to the glycosaminoglycans originated from proteoglycans^{31,32}. HA is usually found in a concentration of 3 mg/mL in a healthy and normal joint³⁰. However, in pathological conditions, a chain of events at molecular level takes place and the glycosaminoglycans are found disintegrated and disperse in the synovial fluid, being contained within the synovial cavity³³. As a consequence, the concentration and volume of SH inside the damaged joint may be reduced up to 50%. The synovial fluid becomes less viscous and, as a result shocks are not properly absorbed, which may impair the articular protection and lubrication³⁴. The presence of inflammatory mediators in the synovial fluid has a relevant role in the pathophysiology of articular diseases. Prostaglandin E2 (PGE2), leukotriene B4 (LTB4), interleukin (IL) 1 β , IL-2, IL-8, interferon (IFN) γ and tumor necrosis factor TNF- α were identified in the synovial fluid of patients with pain, which suggests that these mediators are related to TMJ osteoarthritis²⁴. We believe this may have happened in this case, however we cannot precise which mediators were present nor where, once no laboratorial analysis was performed. The financial problems faced by the pa-

tient did not allow the examination of TMJ by nuclear magnetic resonance. If such imaging test could have been performed in T1 and mostly T2 weighted imaging, we might have visualized the presence of these inflammatory changes in one or both cavities, with a mild, moderate or severe hyper signal. Such information would give us an idea of the articular effusion level and its location regarding the TMJ. If a new magnetic resonance of the TMJ could have been obtained after the sequential infiltration with sodium hyaluronate, we would have better understood what had happened with the disc and if there had been any morphological or positioning changes and if the effusion remained, diminished or disappeared, once the intra-articular pain, the reciprocal noise and jaw deviation were eliminated.

Studies analyzing knee joint diseases observed an association between increase of the TNF- α and IL-6 serum values and levels of pain and function limitation³⁵. Therefore it is evident the role of inflammation and its mediators in the pathophysiology, signals and symptoms and evolution of articular diseases, being TMD included.

The viscosupplementation may improve lubrication (qualitatively and quantitatively), biomechanics and the elimination or reduction of pain, since it aims at restoring the rheological properties of the synovial fluid, having it a mechanical, analgesic, anti-inflammatory and chondroprotective objective³². The articular infiltration with sodium hyaluronate, as performed in this case, increased the concentration of hyaluronic acid in the synovial fluid, facilitating the releasing of adherence areas. It probably promoted articular mobility and diminished the secondary joint wear and it also allowed the synovial fluid to better circulate, which helped nutrients and metabolites diffusion into a vascular tissues. HA may also reduce inflammatory mediators levels, contributing to the relief of pain in the articulations^{33,33}. Good results have been obtained with this intervention in various TMD due to mechanical and metabolic characteristics of HA^{7,36-38}.

The present paper is a case report, and regardless of its low evidence, it generates a hypothesis.

Results found in a meta-analysis study³⁸ suggested that HA application can improve TMD clinical signals in comparison with placebo. However, results are inconclusive due to the absence of well designed and controlled randomized clinical trials. Selected studies indicated some positive evidences, however some methodological problems and incomplete reports influenced their validity and reproducibility. Furthermore, different doses of SH with distinct molecular weights and different cycles of treatment were used, compromising the selection of trials to the systematic review.

The patient of the present study received a sequence of alternate infiltrations of SH that aimed at improving viscosupplementation and posterior visco-induction, generating a possible synergism between the different substances applied into the articulation. Another relevant aspect of this strategy of sequential infiltrations is that the initial application of the lower molecular weight SH possibly contributed with its interaction at a molecular/cellular level and has led to the decrease of pain. When the higher molecular weight SH was applied our aim was to diminish the action of phospholipase A2 (PLA₂), which is secreted by

synoviocytes, chondrocytes and osteoblasts into the synovial fluid, and may lead to a degenerative process. As the inhibition of (PLA₂) is dose dependent, the higher the molecular weight and HA concentration used the higher will be (PLA₂) inhibition⁴⁰. Therefore, the exogenous use of such viscoelastic substance, with such molecular weight, probably contributed to the relief of pain and reestablished the homeostasis of the synovial fluid and the biomechanics of the TMJ. The last dose, with a higher molecular weight, was used as viscoelastic reinforcement. The most common side effect associated with viscosupplementation is the occurrence of local reaction at the injection site, such as transient pain and swelling⁴¹⁻⁴⁴. The patient described in this paper did not present any side effects, neither local nor systemic, during the monthly applications. The monthly frequency of our applications seemed to work in an effective and safe way in our research. However, the literature suggests weekly and fortnightly cycles^{7,18,36,45}. The present study performed four cycles with an application a month, which generates a higher cost in the treatment. Such aspects should be taken into consideration and discussed with patients when the treatment is agreed with them, taking into consideration the costs/benefits aspects of it at the moment.

Randomized clinical trials should be conducted to verify what is the best cycle and what would be the impact of using first the higher molecular SH followed by the lower molecular weight one, or even comparing this modality of treatment with isolated arthrocentesis, arthrocentesis and viscosupplementation regarding the benefits of the different treatments over time.

CONCLUSION

The present study suggests that cycles of viscosupplementation with SH of different molecular weights may present excellent long term results in the control of signals and symptoms of TMD of articular origin, as the therapeutic benefits were kept for a period of four years, without the need for annual maintenance cycles.

REFERENCES

- Locker D, Grushka M. Prevalence of oral and facial pain and discomfort: preliminary results of a mail survey. *Community Dent Oral Epidemiol.* 1987;15(3):169-72.
- Wilkes CH. Structural and functional alterations of the temporomandibular joint. *Northwest Dent.* 1978;57(5):287-94.
- Escoda-Francolí J, Vázquez-Delgado E, Gay-Escoda C. Scientific evidence on the usefulness of intraarticular hyaluronic acid injection in the management of temporomandibular dysfunction. *Med Oral Patol Oral Cir Bucal.* 2010;15(4):e644-8.
- Li C, Zhang Y, Lv J, Shi Z. Inferior or double joint spaces injection versus superior joint space injection for temporomandibular disorders: a systematic review and meta-analysis. *J Oral Maxillofac Surg.* 2012;70(1):37-44.
- Grossmann E, Januzzi E, Iwaki Filho L. O uso do hialuronato de sódio no tratamento das disfunções temporomandibulares articulares. *Rev Dor.* 2013;14(4):301-6.
- Yeung RW, Chow RL, Samman N, Chiu K. Short-term therapeutic outcome of intra-articular high molecular weight hyaluronic acid injection for nonreducing disc displacement of the temporomandibular joint. *Oral Surg Oral Med Oral Pathol Oral Radiol Endod.* 2006;102(4):453-61.
- Guarda-Nardini L, Rossi A, Ramonda R, Punzi L, Ferronato G, Manfredini D. Effectiveness of treatment with viscosupplementation in temporomandibular joints with or without effusion. *Int J Oral Maxillofac Surg.* 2014;43(10):1218-23.
- Ghosh P, Guidolin D. Potential mechanism of action of intra-articular hyaluronan therapy in osteoarthritis: are the effects molecular weight dependent? *Semin Arthritis Rheum.* 2002;32(1):10-37.
- Fraser JR, Laurent TC, Laurent UB. Hyaluronan: its nature, distribution, functions and turnover. *J Intern Med.* 1997;242(1):27-33.
- Asari A, Miyauchi S, Matsuzaka S, Ito T, Kominami E, Uchiyama Y. Molecular weight-dependent effects of hyaluronate on the arthritic synovium. *Arch Histol Cytol.* 1998;61(2):125-35.
- Bertolami CN, Gay T, Clark GT, Rendell J, Shetty V, Liu C, et al. Use of sodium hyaluronate in treating temporomandibular joint disorders: a randomized, double-blind, placebo-controlled clinical trial. *J Oral Maxillofac Surg.* 1993;51(3):232-42.
- Migliore A, Procopio S. Effectiveness and utility of hyaluronic acid in osteoarthritis. *Clin Cases Miner Bone Metab.* 2015;12(1):31-3.
- Kwecinski JJ, Dorosz SG, Ludwig TE, Abubacker S, Cowman MK, Schmidt TA. The effect of molecular weight on hyaluronan's cartilage boundary lubricating ability alone and in combination with proteoglycan 4. *Osteoarthritis Cartilage.* 2011;19(11):1356-62.
- Smith MM, Ghosh P. The synthesis of hyaluronic acid by human synovial fibroblasts is influenced by the nature of the hyaluronate in the extracellular environment. *Rheumatol Int.* 1987;7(3):113-22.
- Kopp S, Akerman S, Nilner M. Short-term effects of intra-articular sodium hyaluronate, glucocorticoid, and saline injections on rheumatoid arthritis of the temporomandibular joint. *J Craniomandib Disord.* 1991;5(4):231-8.
- Xinmin Y, Jian H. Treatment of temporomandibular joint osteoarthritis with viscosupplementation and arthrocentesis on rabbit model. *Oral Surg Oral Med Oral Pathol Oral Radiol Endod.* 2005;100(3):e35-8.
- Grossmann E. O uso de artrocentese e de lavagem articulação temporomandibular em pacientes com deslocamento anterior do disco sem redução. *Rev Dor.* 2001;3(3):97-102.
- Aktas I, Yalcin S, Sencer S. Prognostic indicators of the outcome of arthrocentesis with and without sodium hyaluronate injection for the treatment of disc displacement without reduction: a magnetic resonance imaging study. *Int J Oral Maxillofac Surg.* 2010;39(11):1080-5.
- Zhang ZK, Ma XC, Gao S, Gu ZY, Fu KY. Studies on contributing factors in temporomandibular disorders. *Chin J Dent Res.* 1999;2(3-4):7-20.
- Millon-Cruz A, Martín-Granizo R, Encinas A, Berquer A. Relationship between intra-articular adhesions and disc position in temporomandibular joints: magnetic resonance and arthroscopic findings and clinical results. *J Craniomaxillofac Surg.* 2015;43(4):497-502.
- Grossmann E, Munerato MC. Aspectos anátomo-fisiológicos da articulação temporomandibular. *Rev Fac Odonto Univ Passo Fundo.* 1996;1(2):11-20.
- Aiken A, Bouloux G, Hudgins P. MR imaging of the temporomandibular joint. *Magn Reson Imaging Clin N Am.* 2012;20(3):397-412.
- de Leeuw R, Klasser GD. Orofacial pain: guidelines for classification, assessment, diagnosis, and management. 5thed. Chicago: Quintessence publ. Co. 2013. 301p.
- Kim YK, Kim SG, Kim BS, Lee JY Yun PY, Bae JH, et al. Analysis of the cytokine profiles of the synovial fluid in a normal temporomandibular joint: preliminary study. *J Craniomaxillofac Surg.* 2012;40(8):e337-41.
- Kubota E, Imamura H, Kubota T, Shibata T, Murakami K. Interleukin 1 beta and stromelysin (MMP3) activity of synovial fluid as possible markers of osteoarthritis in the temporomandibular joint. *J Oral Maxillofac Surg.* 1997;55(1):20-7.
- Takahashi T, Tominaga K, Takano H, Ariyoshi W, Habu M, Fukuda J, Maeda H. A decrease in the molecular weight of hyaluronic acid in synovial fluid from patients with temporomandibular disorders. *J Oral Pathol Med.* 2004;33(4):224-9.
- Fujimura K, Kobayashi S, Yoshitake Y, Tsuruoka N, Kaneyama K, Segami N. Electrophoretically separation of the synovial fluid proteins in rabbit temporomandibular arthritis induced by mechanical loading. *J Oral Pathol Med.* 2005;34(9):546-51.
- Matsumoto K, Honda K, Ohshima M, Yamaguchi M, Nakajima I, Mücke P, et al. Cytokine profile in synovial fluid from patients with internal derangement of the temporomandibular joint: a preliminary study. *Dentomaxillofac Radiol.* 2006;35(6):432-41.
- Suzuki T, Segami N, Nishimura M, Nojima T. Coexpression of interleukin-1 β and tumor necrosis factor α in synovial tissues and synovial fluids of temporomandibular joint with internal derangement: comparison with histological grading of synovial inflammation. *J Oral Pathol Med.* 2002;31(9):549-57.
- Clegg TE, Caborn D, Mauffrey C. Viscosupplementation with hyaluronic acid in the treatment for cartilage lesions: a review of current evidence and future directions. *Eur J Orthop Surg Traumatol.* 2013;23(2):119-24.
- Swann DA, Radin EL, Nazimiec M, Weisser PA, Curran N, Lewinnek G. Role of hyaluronic acid in joint lubrication. *Ann Rheum Dis.* 1974;33(4):318-26.
- Rezende MU, de Campos GC. Viscosupplementation. *Rev Bras Ortop.* 2012;47(2):160-4.
- Hepgul S, Akkoc YS, Pehlivan M, Ozturk C, Celebi G, Saracoglu A, et al. The efficacy of intra-articular sodium hyaluronate in patients with reducing displaced disc of the temporomandibular joint. *J Oral Rehabil.* 2002;29(1):80-6.
- Watterson JR, Esdaile JM. Viscosupplementation: therapeutic mechanisms and clinical potential in osteoarthritis of the knee. *J Am Acad Orthop Surg.* 2000;8(5):277-84.
- Stannus OP, Jones G, Blizzard L, Cicuttini FM, Ding C. Associations between serum levels of inflammatory markers and change in knee pain over 5 years in older adults: a prospective cohort study. *Ann Rheum Dis.* 2013;72(4):535-40.
- Guarda-Nardini L, Rossi A, Arboretti R, Bonini S, Stellini E, Manfredini D. Single- or multiple-session viscosupplementation protocols for temporomandibular joint degenerative disorders: a randomized clinical trial. *J Oral Rehabil.* 2015;42(7):521-8.
- Li C, Long X, Deng M, Li J, Cai H, Meng Q. Osteoarthritic changes after superior and inferior joint space injection of hyaluronic acid for the treatment of temporomandibular joint osteoarthritis with anterior disc displacement without reduction: a cone-beam computed tomographic evaluation. *J Oral Maxillofac Surg.* 2015;73(2):232-44.

38. Lu J, Long X, Deng M, Cheng Y, Li B. [Treatment of temporomandibular joint disc perforation with injection of hyaluronic acid or disc repair]. *Zhonghua Kou Qiang Yi Xue Za Zhi*. 2014;49(8):476-80. Chinese.
39. Shi Z, Guo C, Awad M. WITHDRAWN: Hyaluronate for temporomandibular joint disorders. *Cochrane Database Syst Rev*. 2013;8;10:CD002970.
40. Tanaka E, Detamore MS, Tanimoto K, Kawai N. Lubrication of the temporomandibular joint. *Ann Biomed Eng*. 2008;36(1):14-29.
41. Altman RD, Moskowitz R. Intraarticular sodium hyaluronate (Hyalgan) in the treatment of patients with osteoarthritis of the knee: a randomized clinical trial. Hyalgan Study Group. *J Rheumatol*. 1998;25(11):2203-12.
42. Kolarz G, Kotz R, Hochmayer, I. Long-term benefits and repeated treatment cycles of intra-articular sodium hyaluronate (Hyalgan) in patients with osteoarthritis of the knee. *Semin Arthritis Rheum*. 2003;32(5):310-9.
43. Neustadt DH. Long-term efficacy and safety of intra-articular sodium hyaluronate (Hyalgan) in patients with osteoarthritis of the knee. *Clin Exp Rheumatol*. 2003;21(3):307-11.
44. Phiphobmongkol V, Sudhasaney V. The effectiveness and safety of intra-articular injection of sodium hyaluronate (500-730 kDa) in the treatment of patients with painful knee osteoarthritis. *J Med Assoc Thai*. 2009;92(10):1287-94.
45. Guarda-Nardini L, Cadorin C, Frizziero A, Ferronato G, Manfredini D. Comparison of 2 hyaluronic acid drugs for the treatment of temporomandibular joint osteoarthritis. *J Oral Maxillofac Surg*. 2012;70(11):2522-30.